

**Hybrid Procedure:**  
**Carotid Artery Stenting**  
**Combined with MVR + Bypass**  
**Surgery in Hybrid Room**

**Amit Segev, MD**  
**Boris Orlov, MD**  
**Ehud Raanani, MD**



# Case Presentation

- 74y old male
- Obesity, HTN
- Severe MR, unstable angina
- Coronary angio → 3 vessel CAD
- → planned for emergent MVR + bypass surgery
- Pre-operative carotid Doppler
  - RICA – 100%
  - LICA – 90%

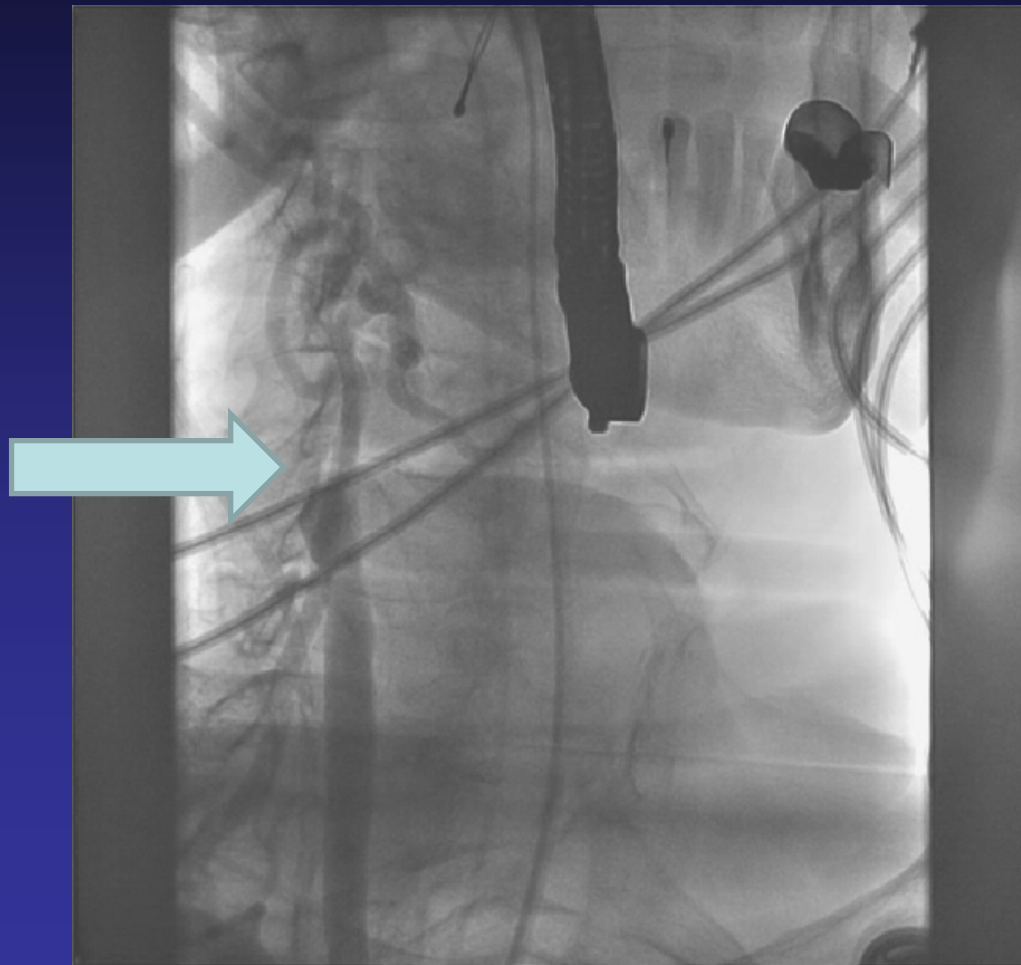


# Protocol for Hybrid Intervention

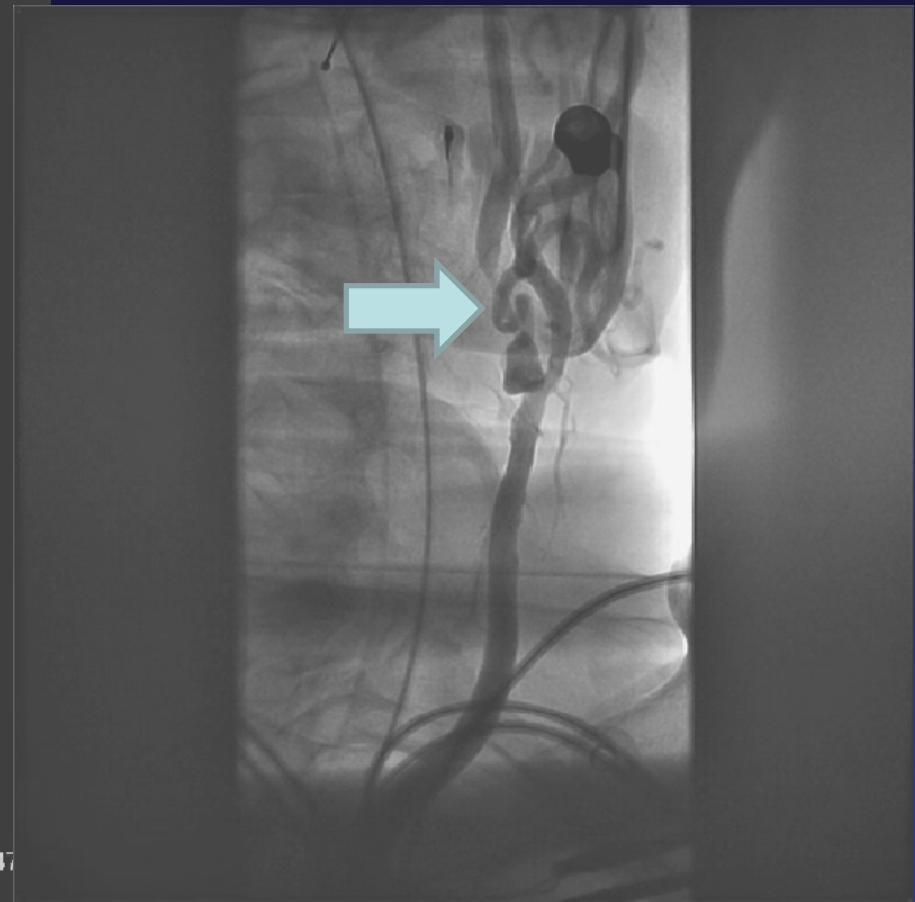
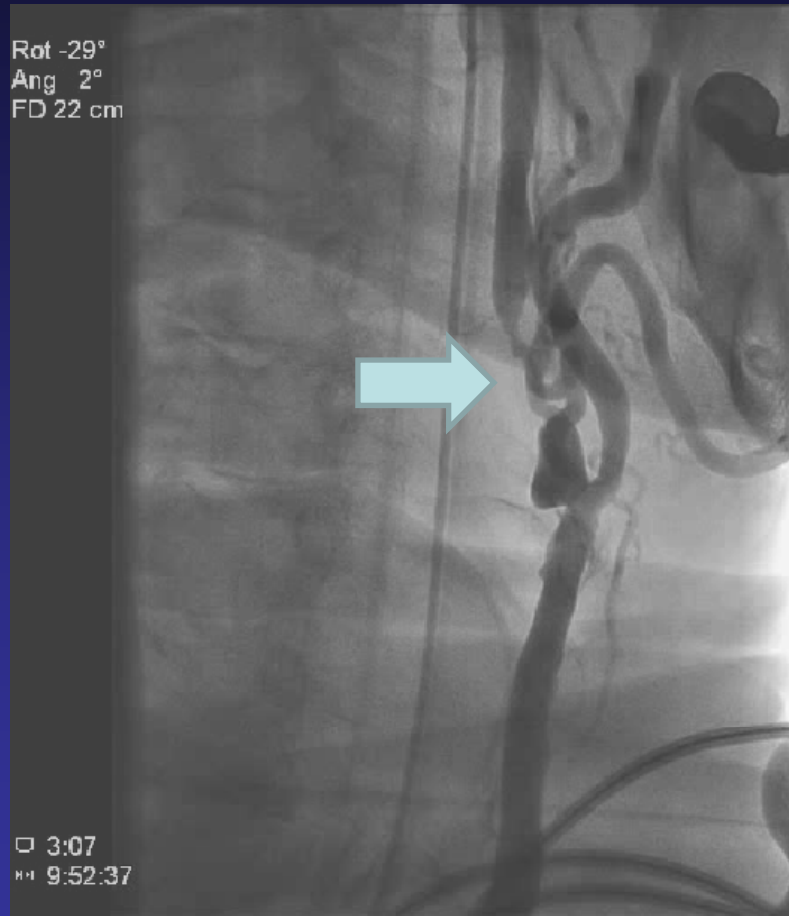- Carotid stenting (CAS), bypass, and MVR done in same procedure in hybrid room
- Patient on chronic aspirin
- Before anesthesia – plavix loading 300mg
- CAS via femoral artery under full heparinization + aspirin
- At the end of CAS – heart and lung machine, continue full heparinization → bypass + MVR
- At end of surgery plavix is on board protecting carotid stent



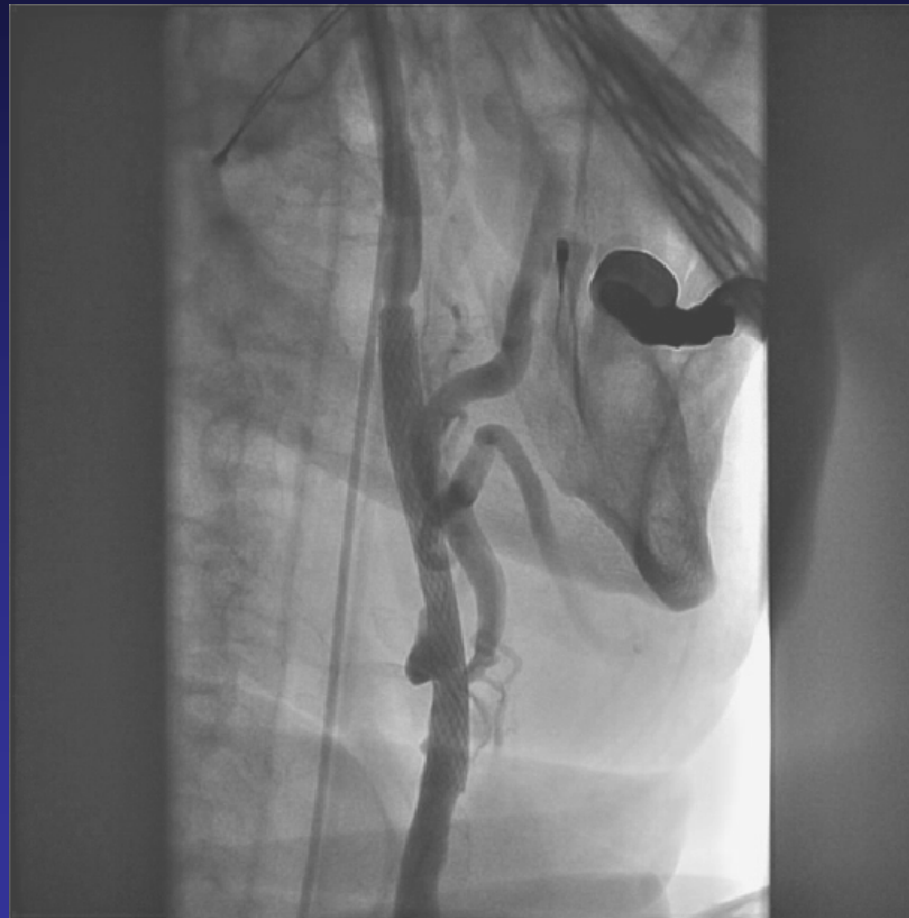# CAS Procedure Occluded RICA



# 90% long LICA lesion

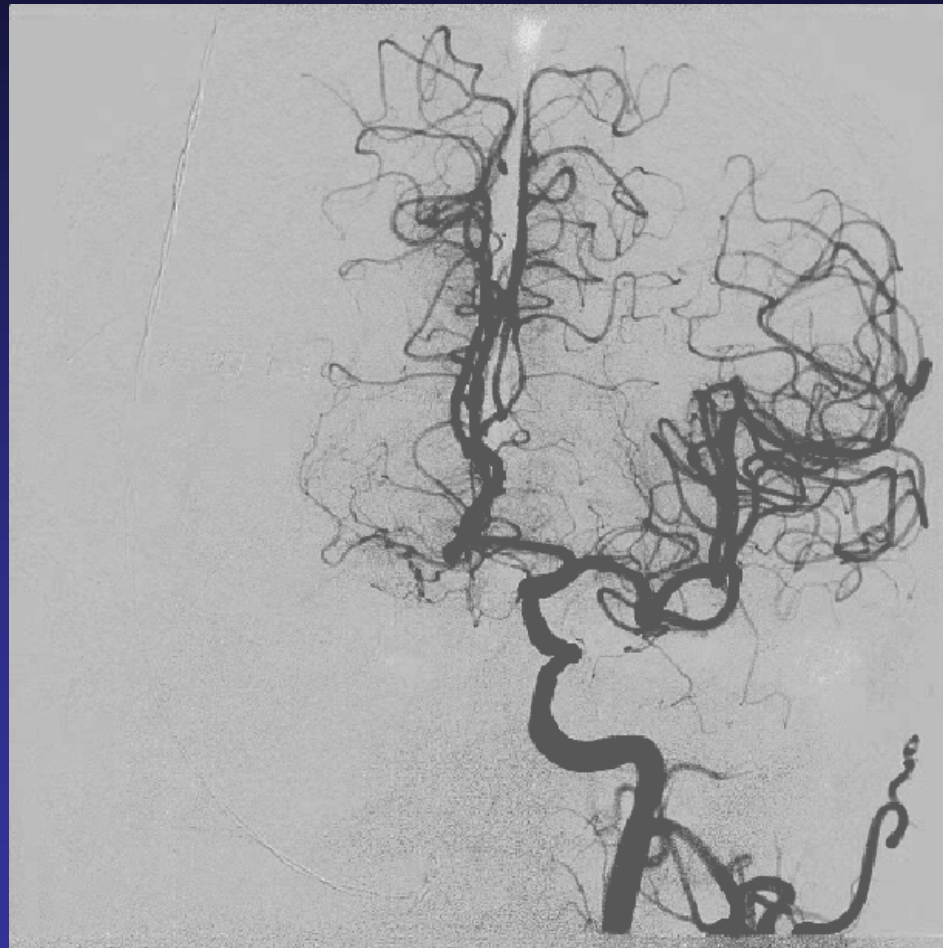


# After stenting using SPIDER FX distal protection device



# Final Cerebral Angio

Note – LICA supplying right hemisphere...



# Follow-up

- No excess post-operative bleeding
- Patient discharged at day 6
- No neurological complications...

