

Paieon IC-PRO Guided PCI

Hana Vaknin-Assa, MD
Ran Kornowski, MD

Rabin Medical Center
Beilinson Hospital
Petach Tikva, Israel

מטרה

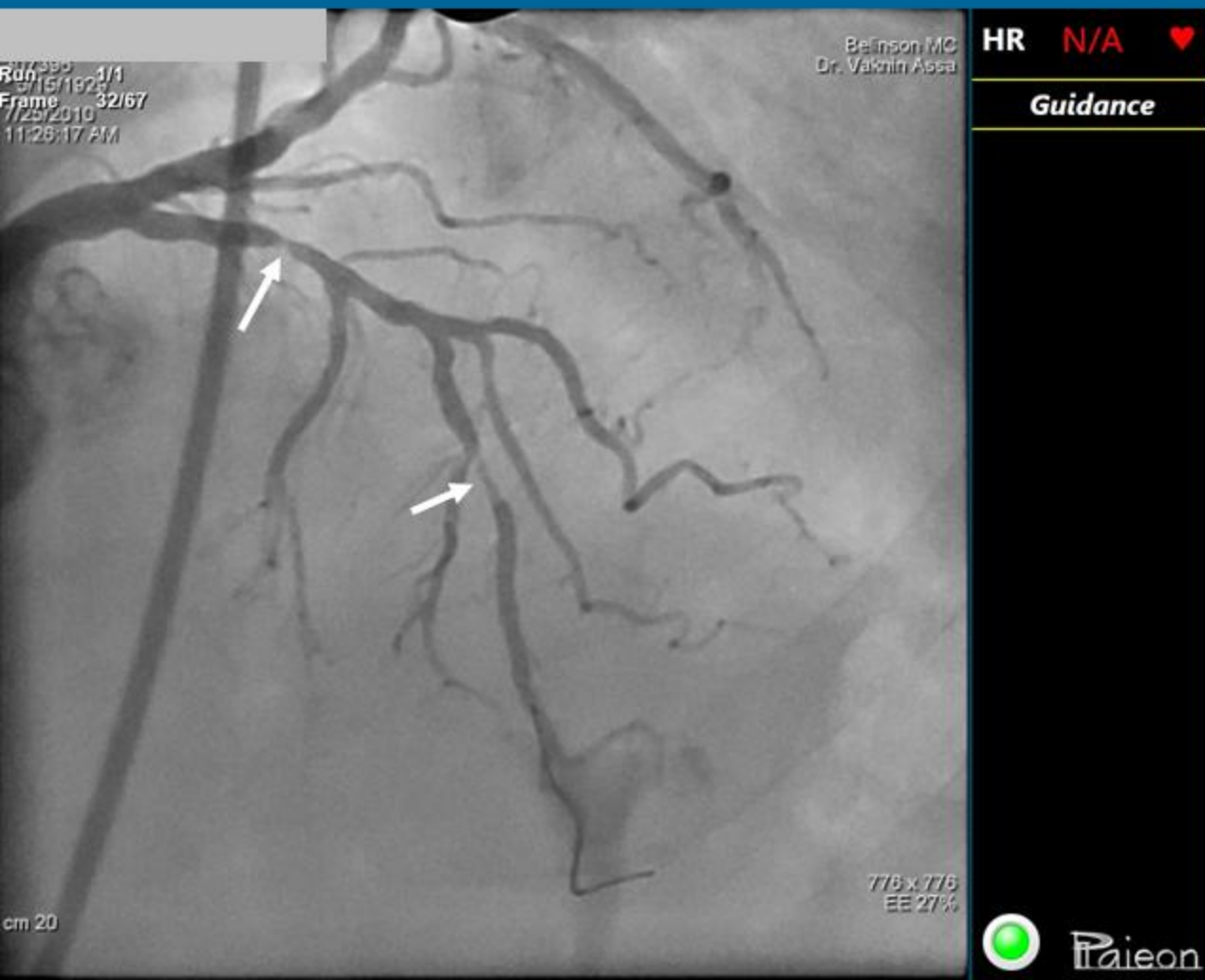
- במצגת הבאה אנו מדגימים שימוש במערכת ניווט תוך כלילית "on line" במהלך שתי פעולות צינתור אנגיופלסטיות בחולים עם coronary artery disease.
- המערכת הינה מסוג IC-PRO Guidance של חברת ההזנק מפארק אפק בראש העין והיא אינטגרטיבית עם מערכת הצינתור הסטנדרטית.

Paieon IC-PRO Guidance

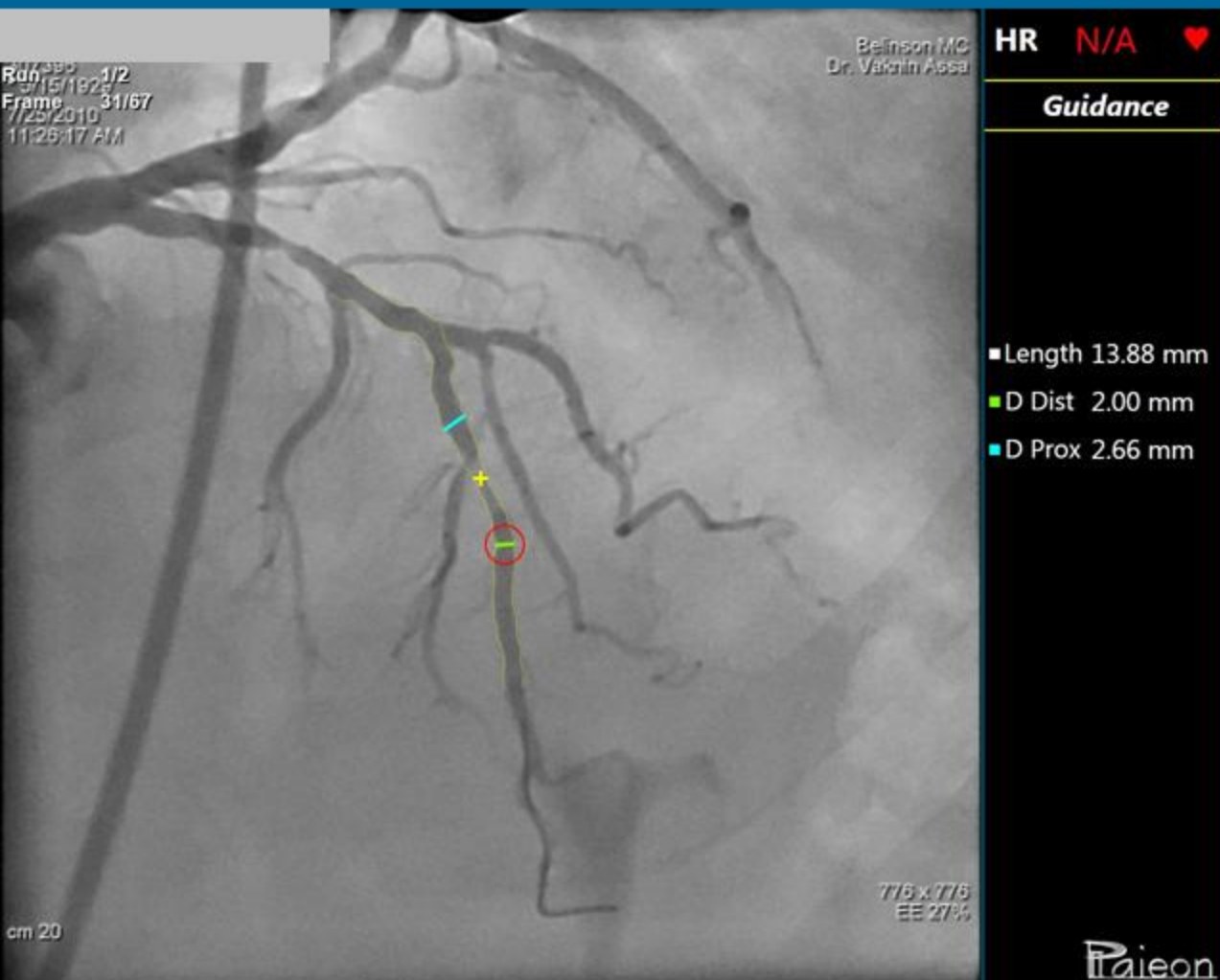
Case 1

81 year-old-female
with symptomatic CAD

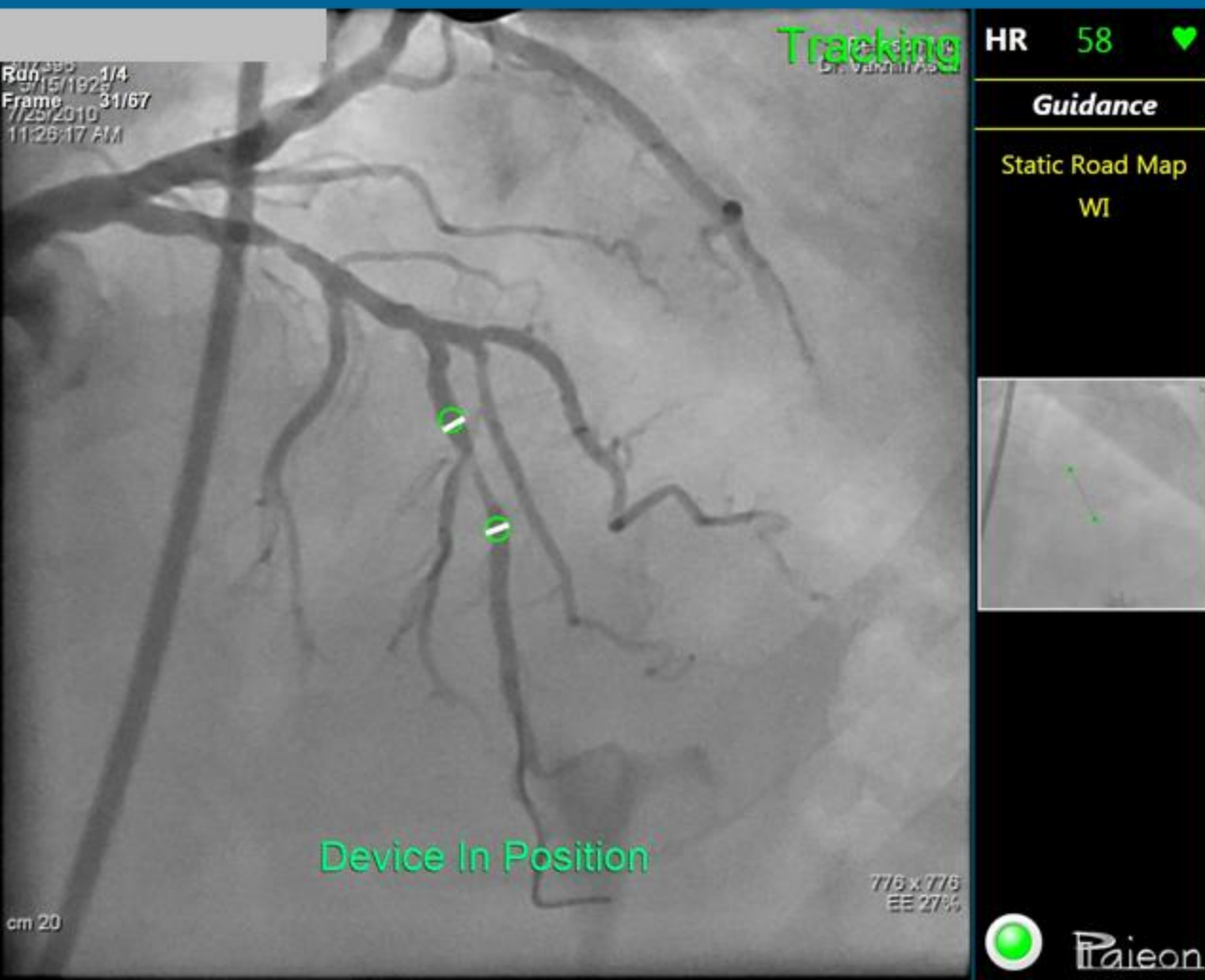
Two stenotic lesions



Planned stent position for distal lesion

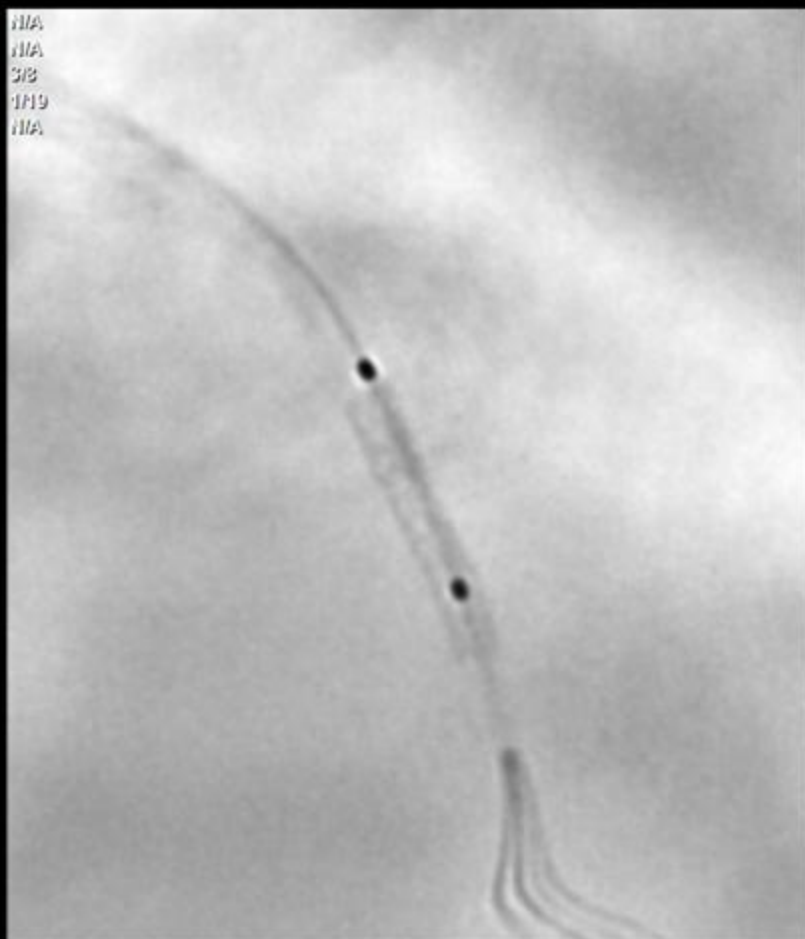

Final tracking result, distal lesion



Distal stent enhancement

LAO
CRAN
Run
Frame
Auto Cal

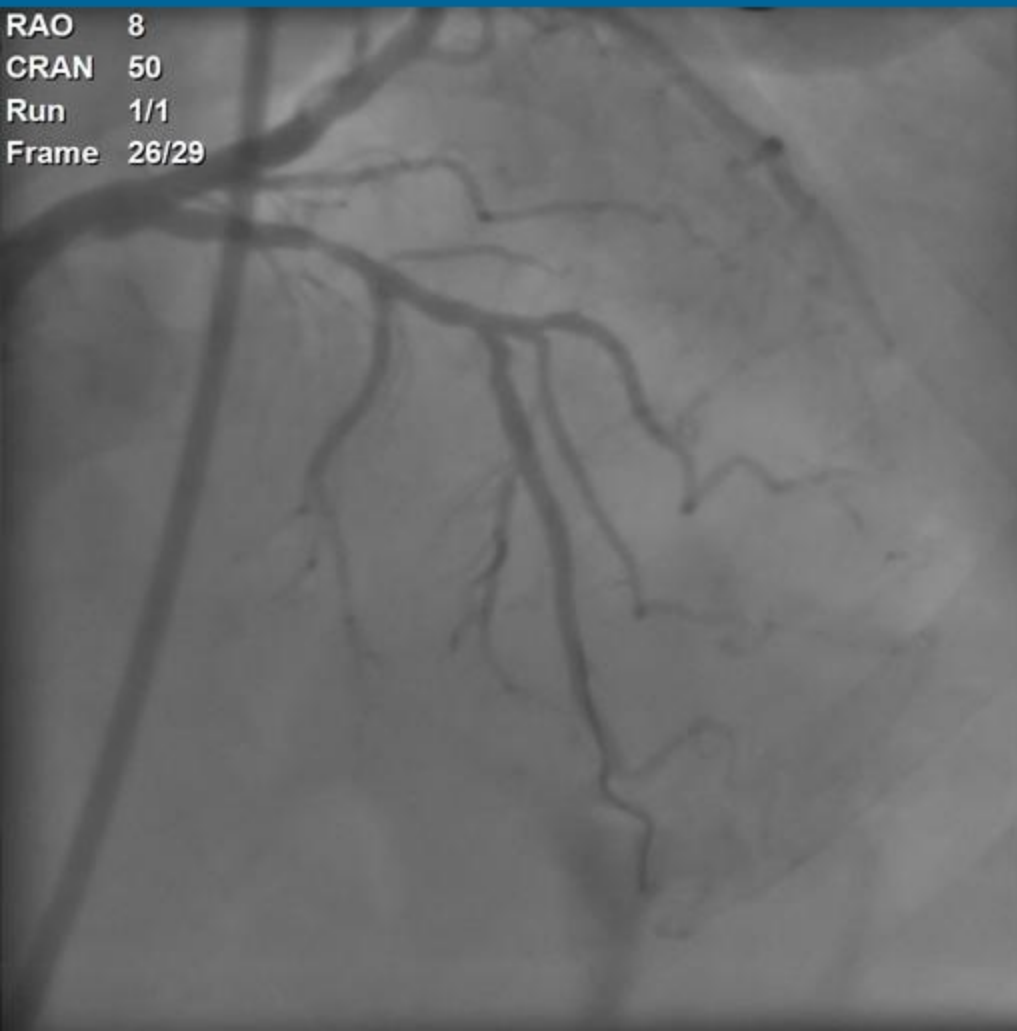

HR N/A ❤️

StentOp

Distal lesion after stent

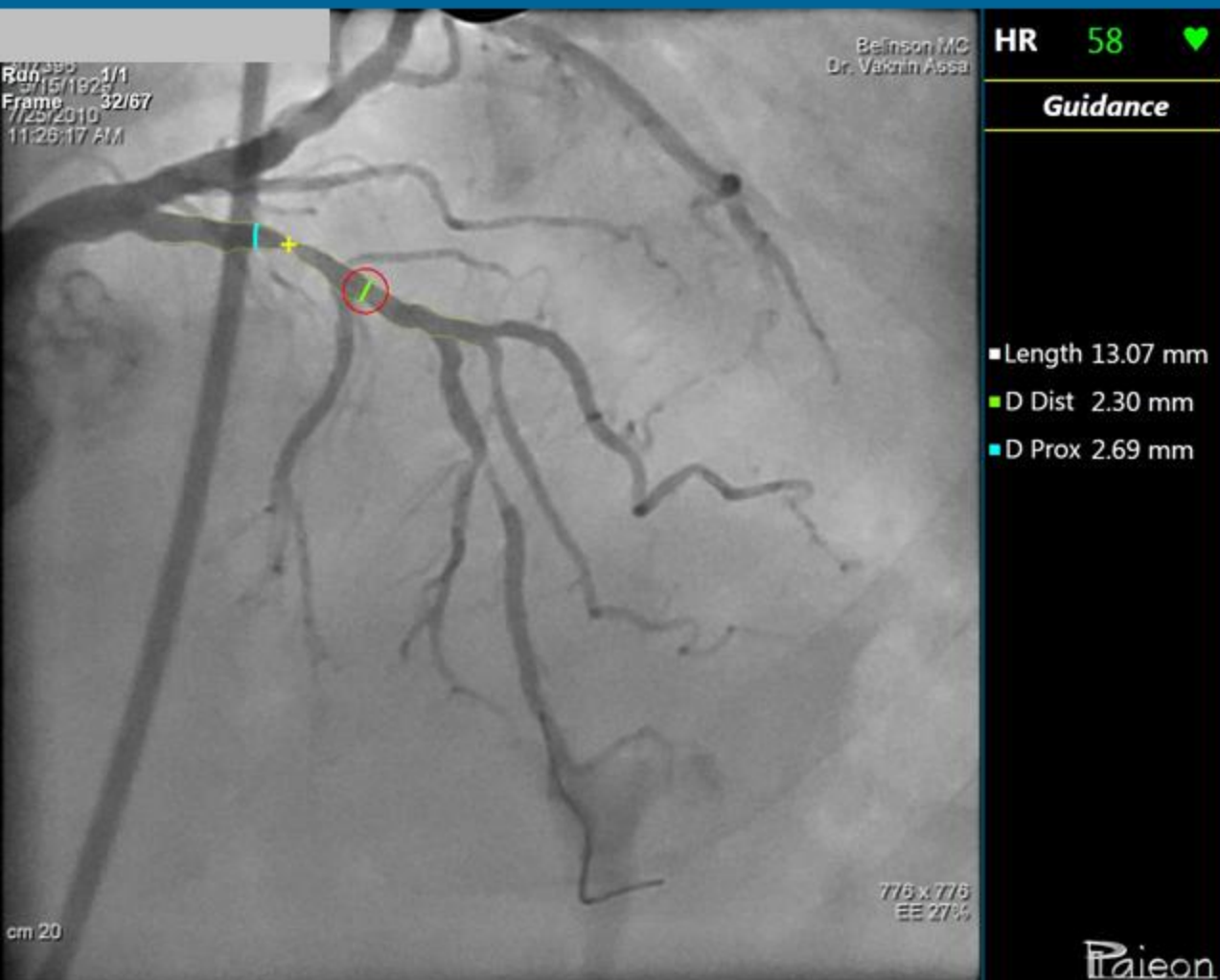
RAO 8
CRAN 50
Run 1/1
Frame 26/29



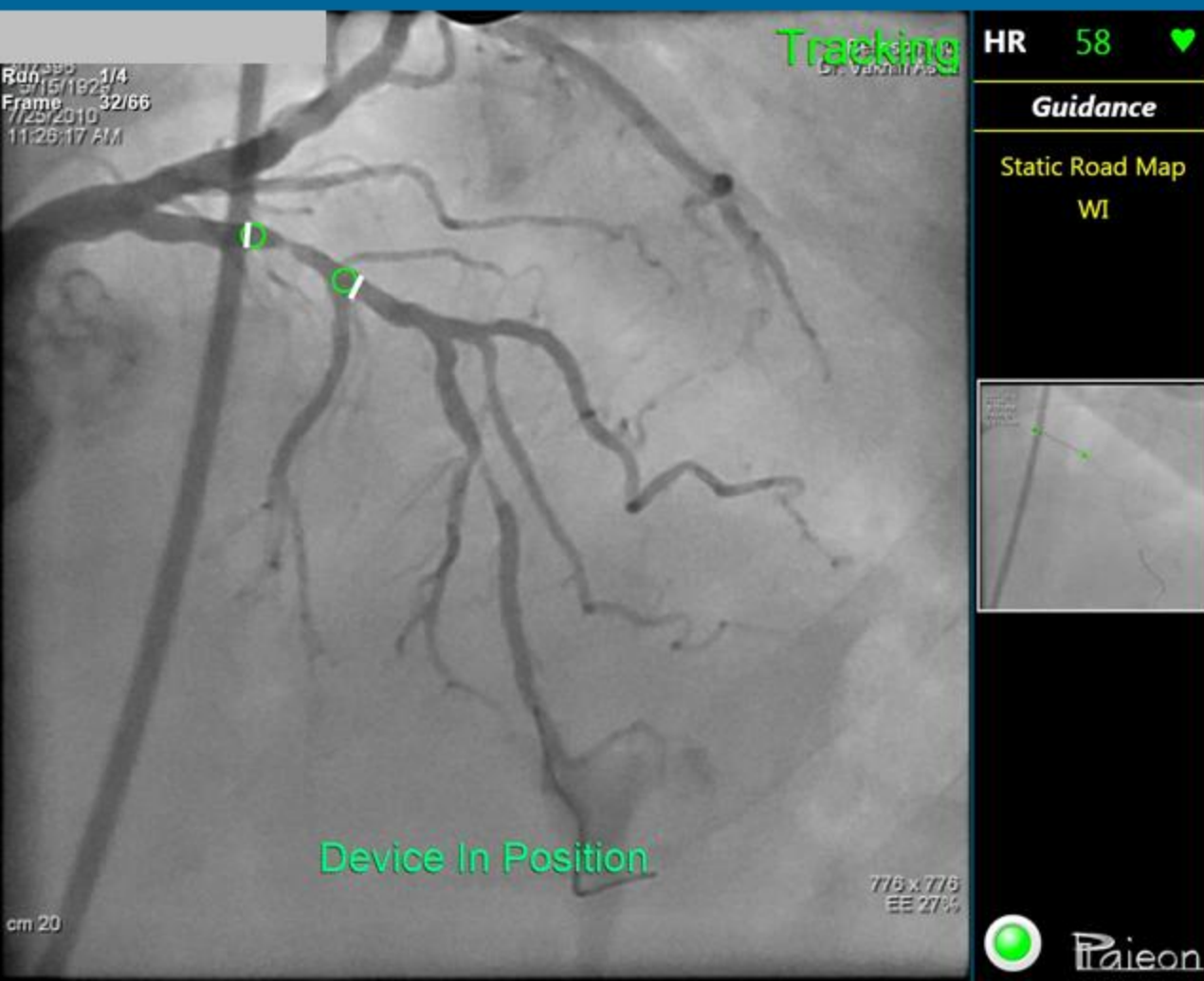
HR 58 

Viewer

Planned stent position for proximal lesion

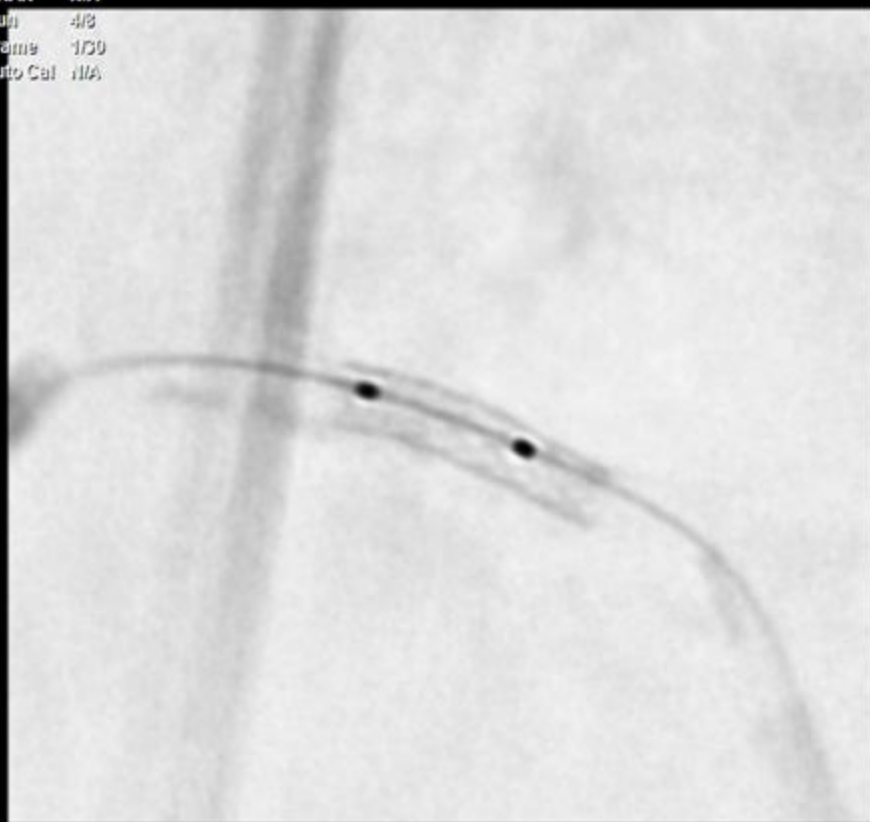

Final tracking result, proximal lesion



Proximal stent enhancement

LAO N/A
CRAN N/A
Run 4/8
Frame 1/20
Auto Cal N/A

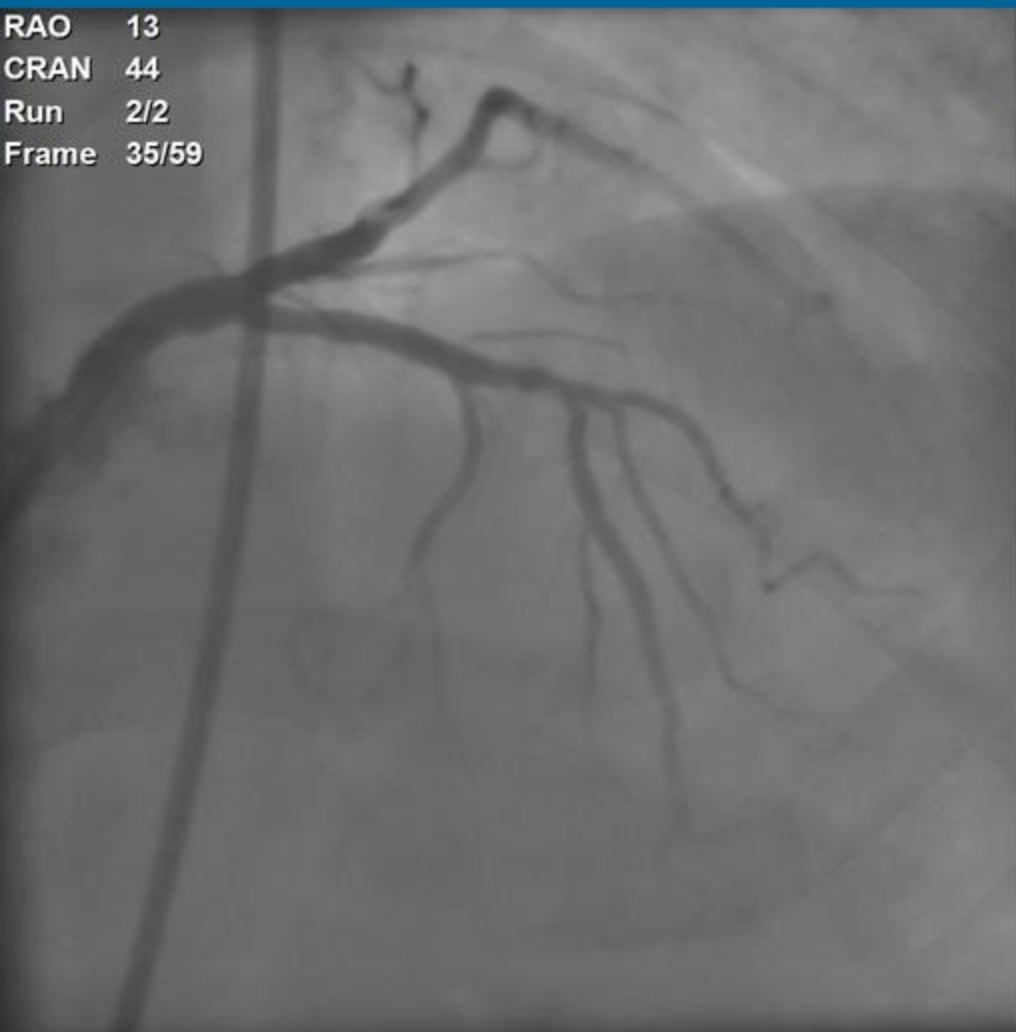


HR N/A ❤️

StentOp

Two lesions after stents

RAO 13
CRAN 44
Run 2/2
Frame 35/59



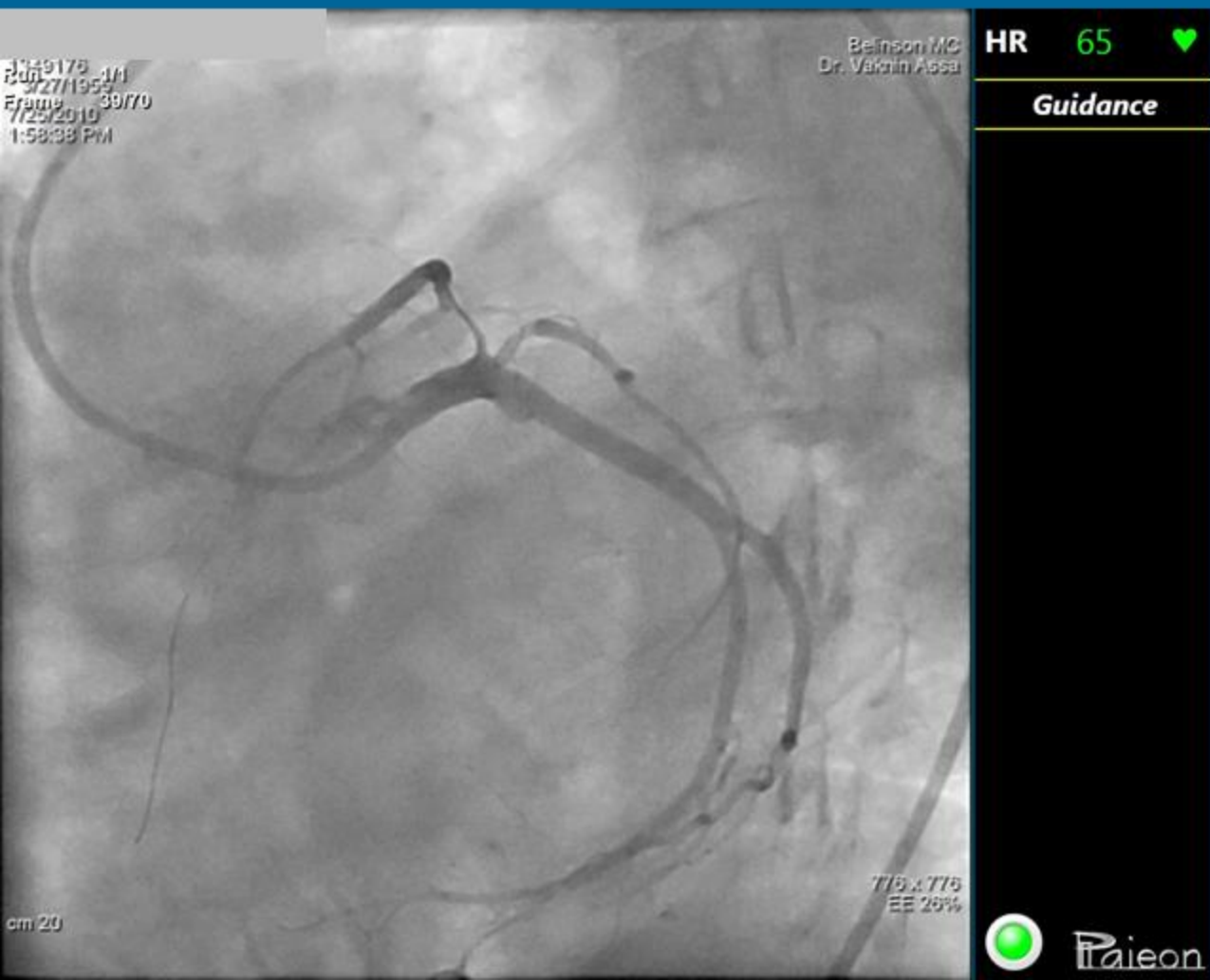
HR 58 

Viewer

Case 2

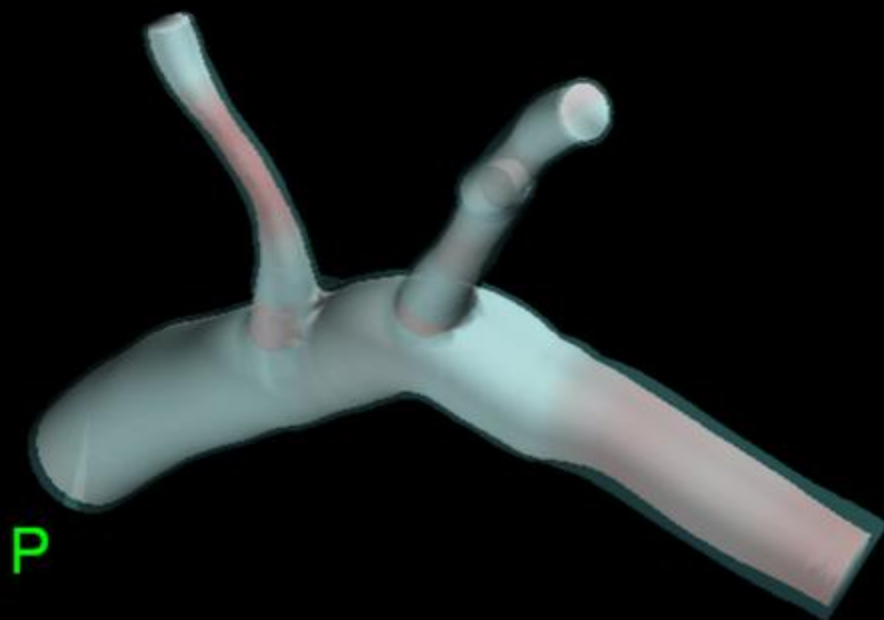
55 year-old-female
with symptomatic CAD

Stenotic lesion



3D model

LAO 41 CAUD 30



HR 65 

CardiOp

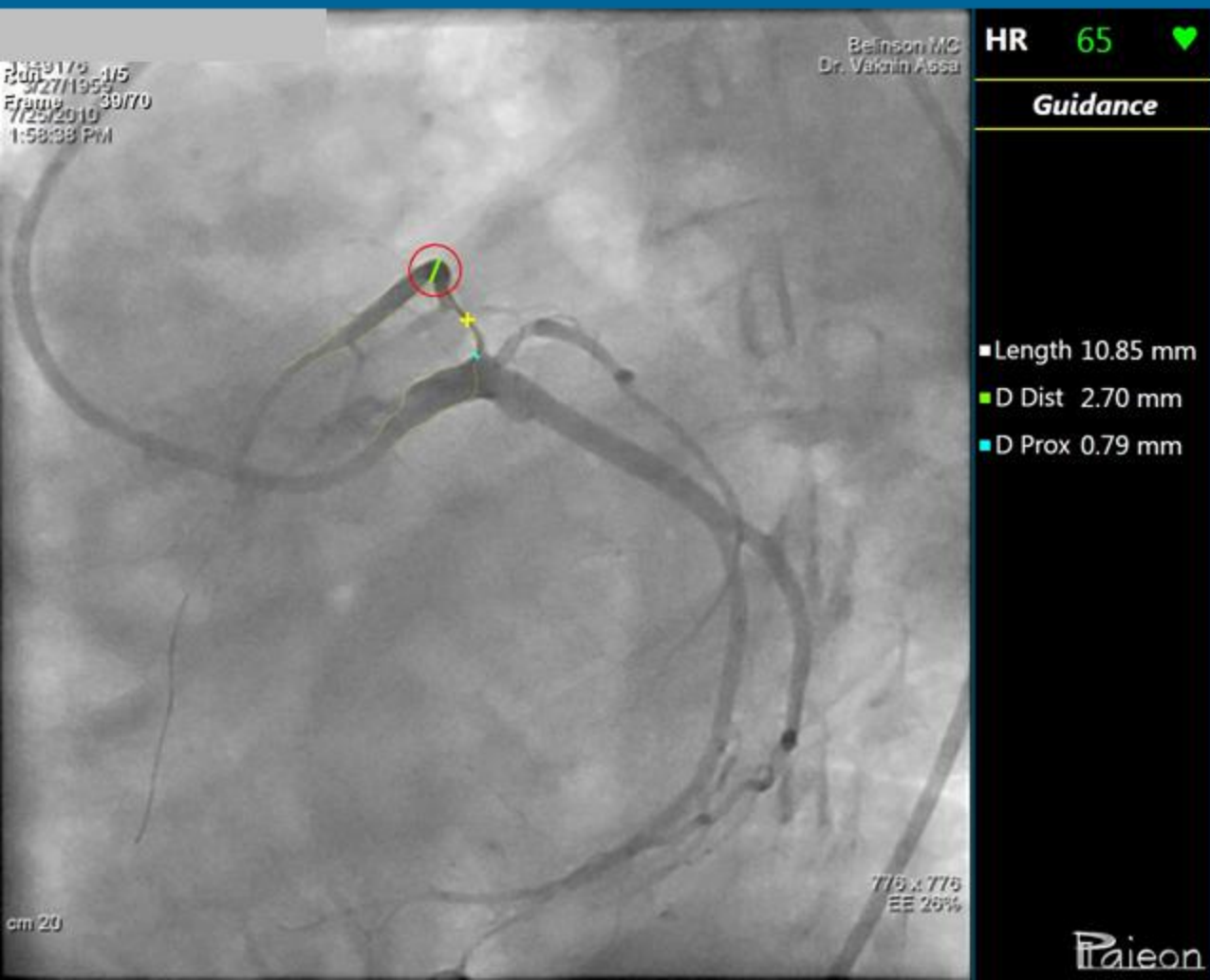
Lesion Data

■ D Stenosis	52	%
■ Length	18.37	mm
■ MLD	1.81	mm

Diameter Data

■ Ref D at MLD	3.73	mm
■ Max D Prox	1.89	mm
■ Max D Dist	2.16	mm
■ Ref D Prox	3.85	mm
■ Ref D Dist	3.55	mm

Planned stent position



Final tracking result

The image displays a medical tracking interface. The main area is a grayscale fluoroscopic image of a blood vessel. A catheter is visible, with its tip positioned at a bifurcation. Two green circles with white arrows point to the catheter tip and a nearby vessel branch. The text "Tracking" is written in green at the top right of the image area. At the bottom center, "Device In Position" is written in green. In the top left corner, there is a data box with the following text: "Run 1/8", "Run 27/195", "Frame 38/70", "7/25/2010", and "1:58:38 PM". In the bottom right corner of the image area, there is text: "T10 x T10" and "EE 26%". A scale bar in the bottom left corner shows "cm 20". On the right side of the interface, there is a vertical panel with a black background. At the top, it shows "HR 65" with a red heart icon. Below that, the word "Guidance" is written in yellow. Underneath, "Static Road Map" and "WI" are displayed in yellow. A small inset image shows a zoomed-in view of the vessel with a green line. At the bottom of the panel is the Paieon logo, which consists of a green circle with a white dot inside, followed by the word "Paieon" in white.

Run 1/8
Run 27/195
Frame 38/70
7/25/2010
1:58:38 PM

Tracking

HR 65

Guidance

Static Road Map
WI

Device In Position

T10 x T10
EE 26%

cm 20

Paieon

Lesion after stent

LAO 44
CAUD 28
Run 1/1
Frame 43/74

HR 65 

Viewer

